



Axel Cappelen

Axel H. Cappelen, MD

(1858-1919)

Axel Cappelen

- The Controversy
- The (historical) Context
- The Case
- Epilogue

Axel Cappelen

The Controversy

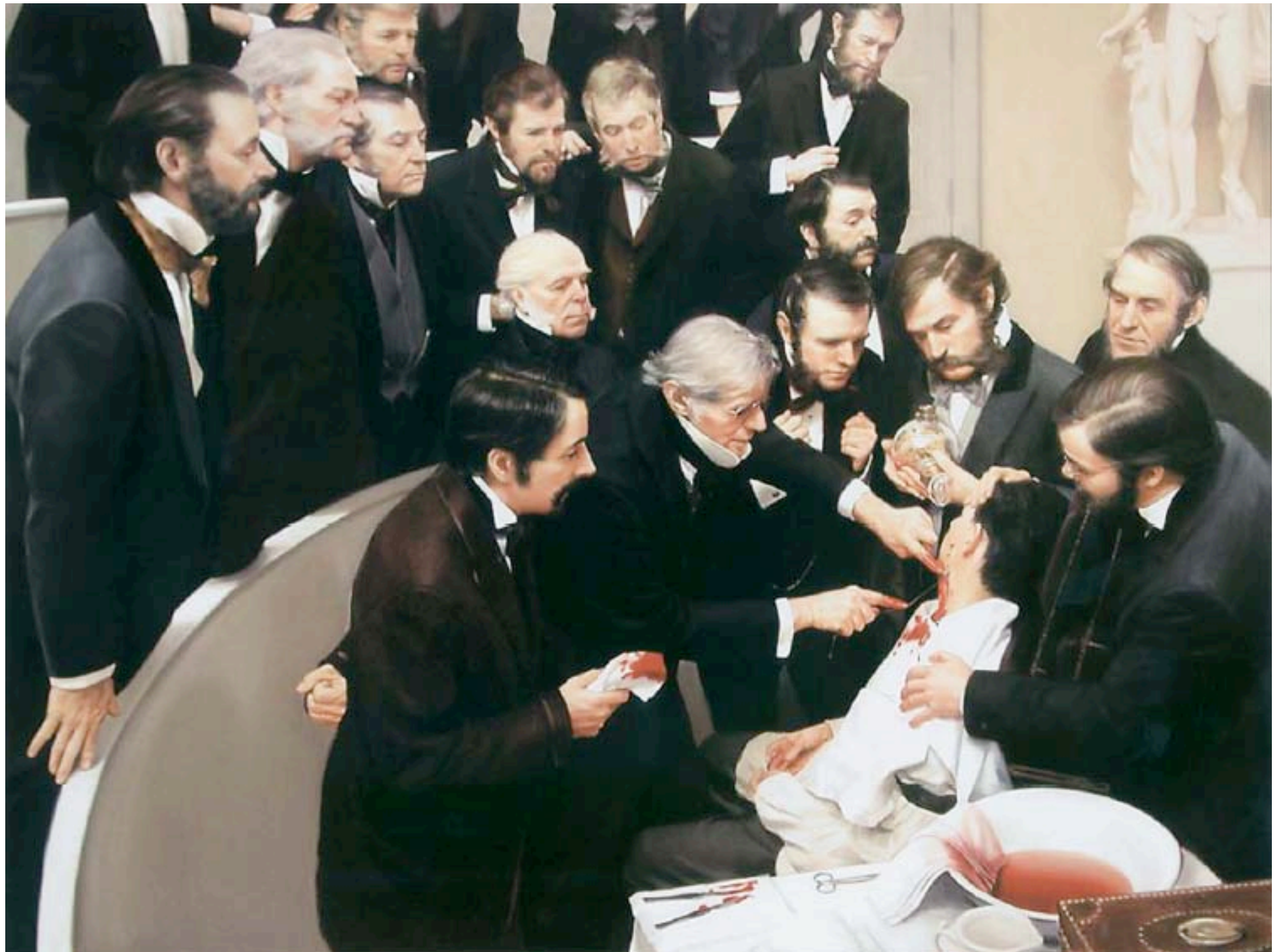

"Anyone who would attempt to operate on the heart should lose the respect of his colleagues"

Theodore Billroth, 1881

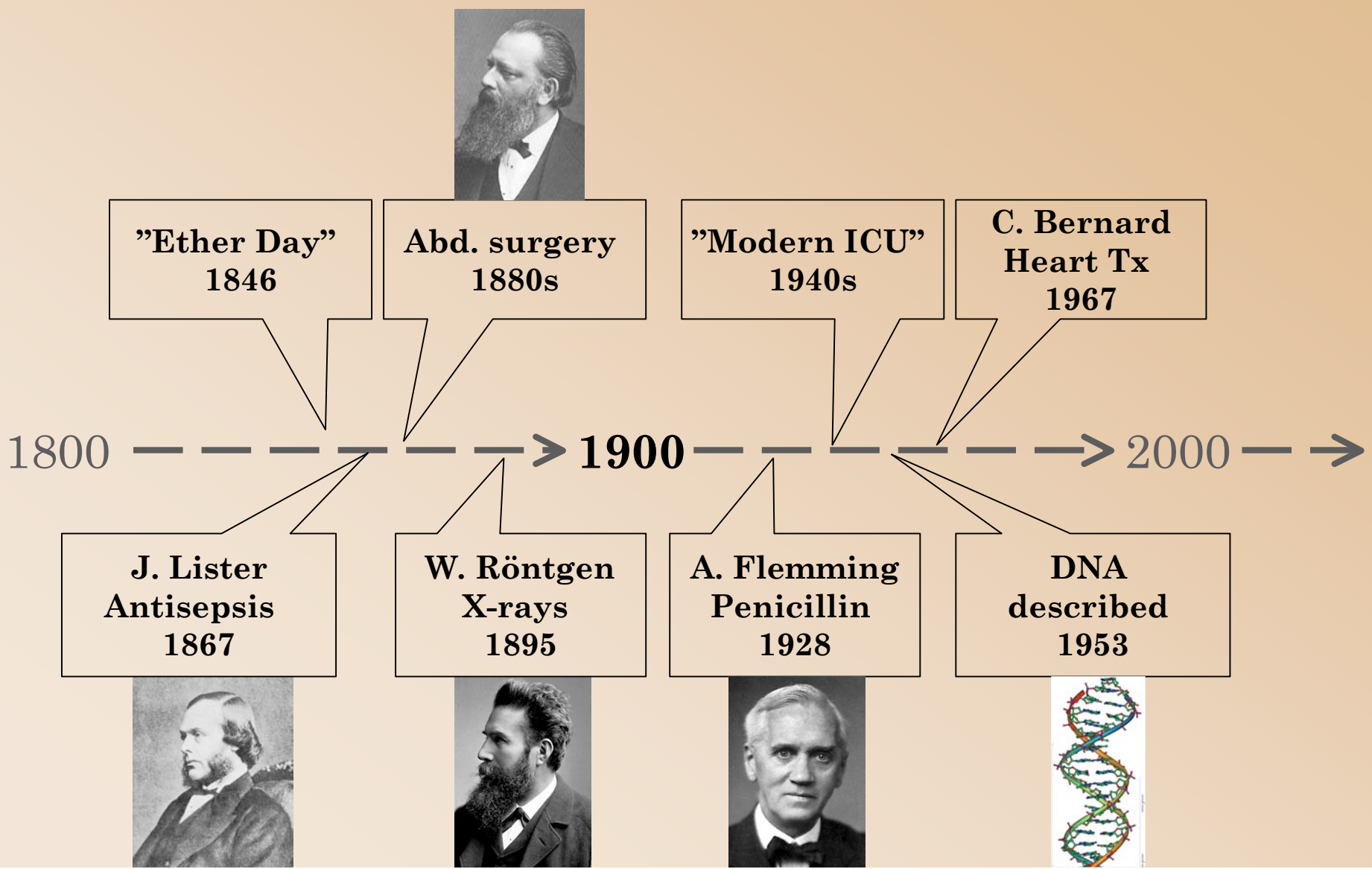
"Surgery of the heart has probably reached the limits set by Nature; no new methods and no new discovery can overcome the natural difficulties that attend a wound of the heart"

Stephen Paget, "Surgery of the Chest", 1896



Axel Cappelen

The Historical Context:




...and picture this:

You're resident surgeon on-call and have:

- Limited surgical training
- No ATLS, BEST, war surgery ...
- No X-ray, CT, ultrasonography...
- No rapid lab-tests...
- No anaesthesiologist... (!)
- No intubation/sedation/mm.relaxation...
- No heart-lung-machine/respiratory support
- No fancy-equipped ICU...
- No antibiotics...

Axel Cappelen

...and this is the hospital !



Stavanger kommunale sykehus 1897.

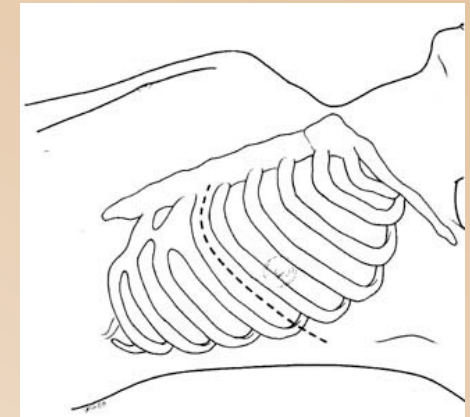
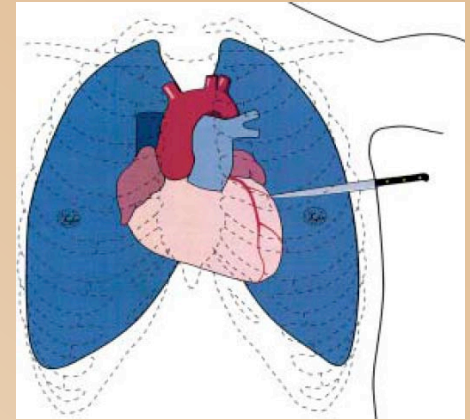
Axel Cappelen

The Case

Time: September 4th, 1895 - towards midnight

Place: National Hospital, Oslo, Norway

- 24-yr old male
- Stab-wound to the left chest
- "exsanguinated"
- First: observation
- Later: left anterolateral thoracotomy
 - (1400 cc blood)
 - (in Chlorophorm anaesthesia)



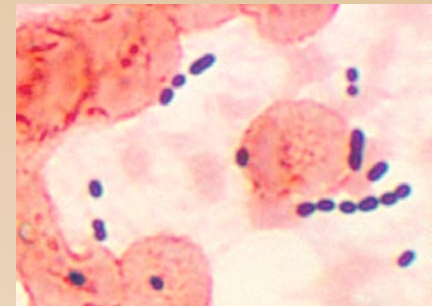
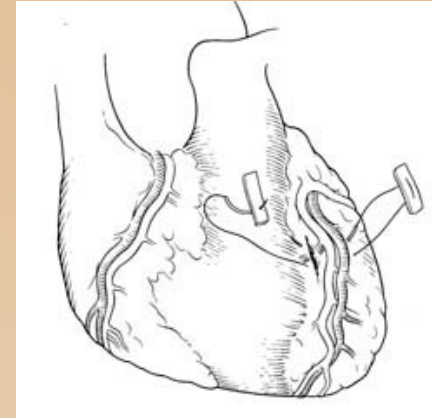
Baksaas & Solberg. *Tidsskr* 2003.

Søreide & Søreide. *J Trauma* 2006; 60(3):653-4.

Axel Cappelen

The Case

- Laceration of left ventricle
 - Arterial injury
- Sutured by Cappelen
- Initially good recovery
- Fever and tachycardia on POD 3
 - Died on September 7 (after 3 days)
- Autopsy: pericarditis, gram-positive diplococci



Axel Cappelen

Epilogue



D. L.
Pericardi
18

IX.
Ueber penetrirende Herzwunden
und Herznaht.
Von
Professor Dr. L. Rehn
in Frankfurt a. M. 1895.

In einem verzweifelten Fall von Stichverletzung des rechten Ventrikel wurde ich durch die andauernde Blutung zum Eingreifen gezwungen. Ich wollte das Möglichste thun, um den Kranken zu retten und so kam ich im Lauf der Operation in die Nothwendigkeit, eine Herznaht auszuführen. Es blieb mir kein anderer Weg, so schwer er war, denn der Patient hätte sich unter meinen Augen verblutet.



in
suture
iac
and

Cardiac suture
1895



Axel Cappelen:

- A pioneer
 - Cardiac suture
 - Introduced antiseptic techniques in Norwegian surgery
 - Pioneered treatment of acute appendicitis in Norway
- A mentor
 - Trained several of the prominent surgical leaders of the time
- A visionary
 - Helped design, draw and finance the building of a modern hospital in Stavanger in the 1900s

Axel Cappelen



Prosjekt MOBA

Pasienthotell
og parkering

Axel Cappelen

Lessons learned...

- The operation was successful, but the patient died...
- Behind all success is plenty of failure!
- Authorities can (and will) be wrong!
- Perseverance pays off - keep on trying!!!

Today:

- Surgery of the wounded heart is mainstay of treatment
- Saves up to 30-40% of those with isolated, penetrating stabwounds of the heart if done in time!

Axel Cappelen

- Be a pioneer!
- Be a mentor (and a mentee !)
- Be a visionary!