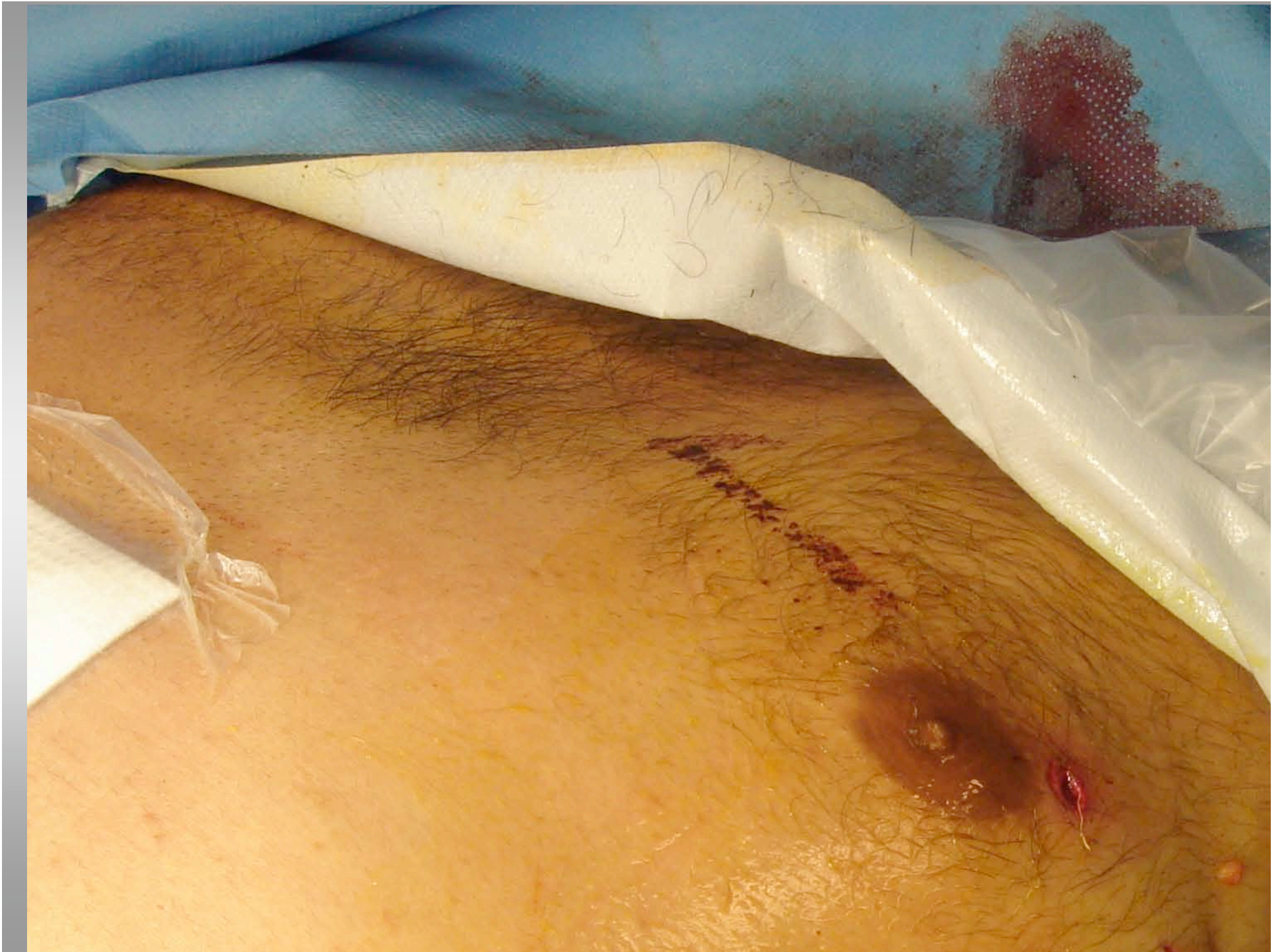

## 28 year old male

---

- M            GSW, transported by taxi, walks into the ED
  - I            Left chest, left iliac crest
  - S            Mentally adequate, pale
  - T            ?
-



# Primary survey

---

- A      Talks, sats 99%
- ?
- B      Air entry equal bilaterally
- ?
- C      BP 120/70, pulse 105
- ?
- D      GCS 15
- ?
- E      2 holes - left mamilla, left iliac crest

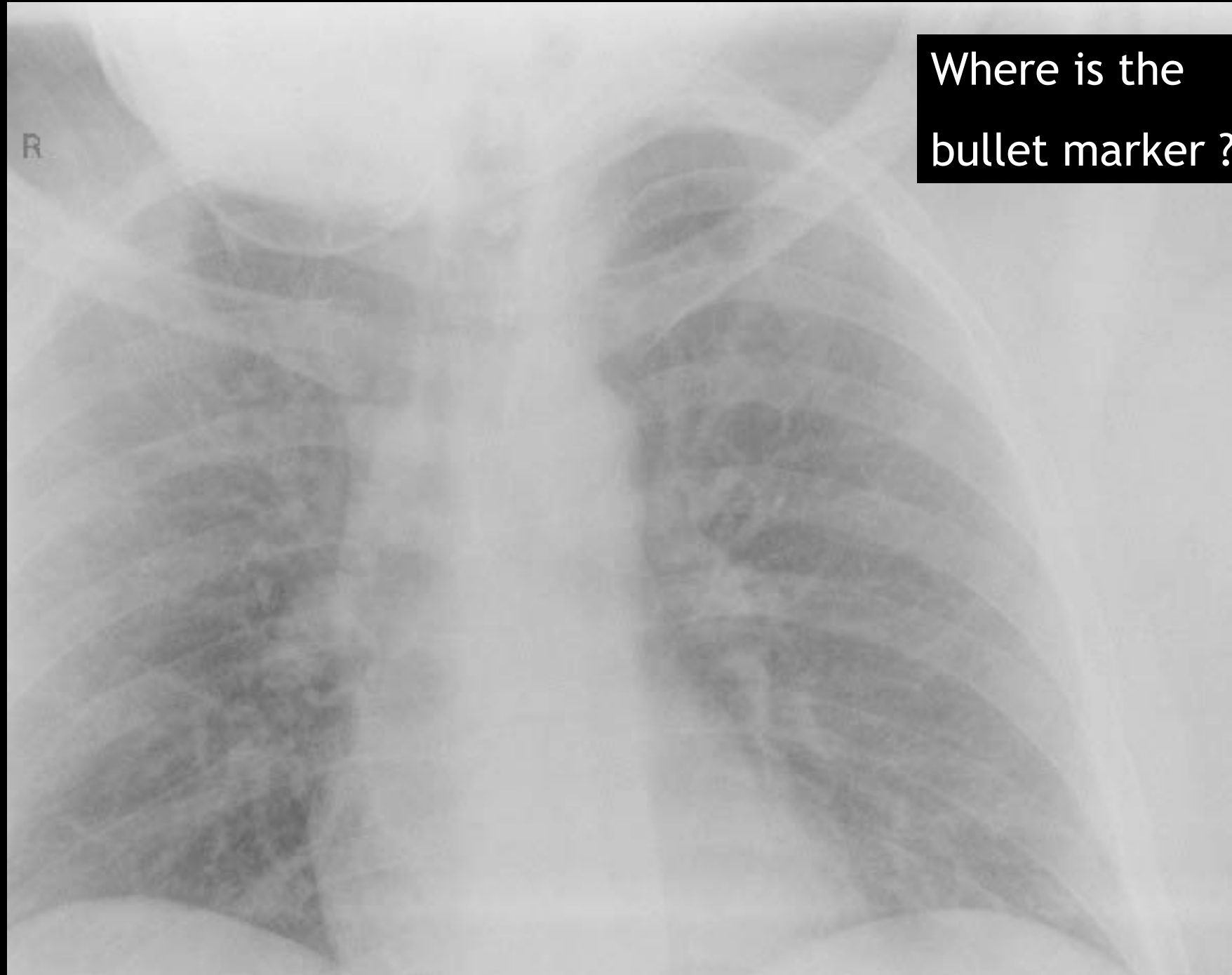
??

---

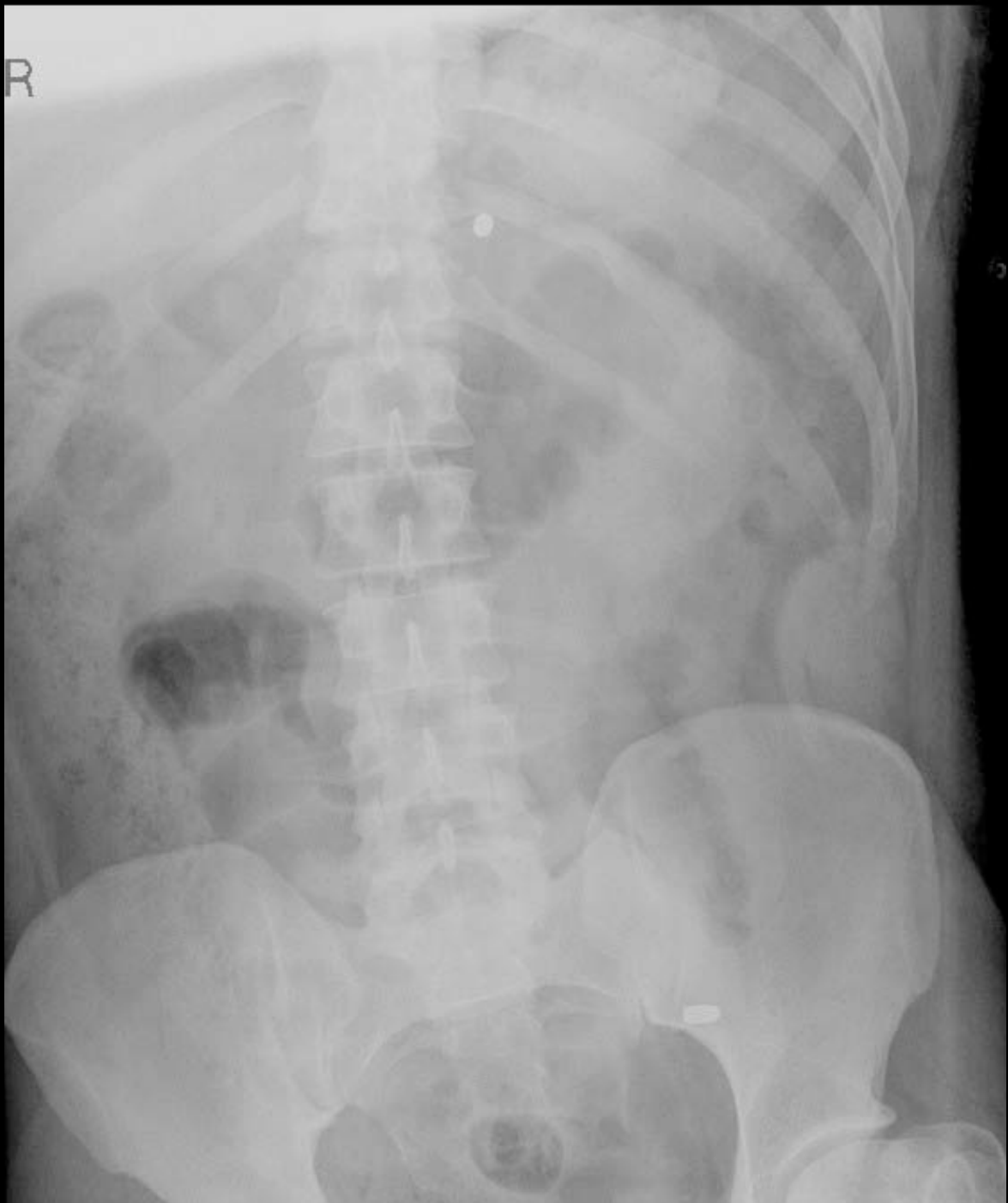# Investigations

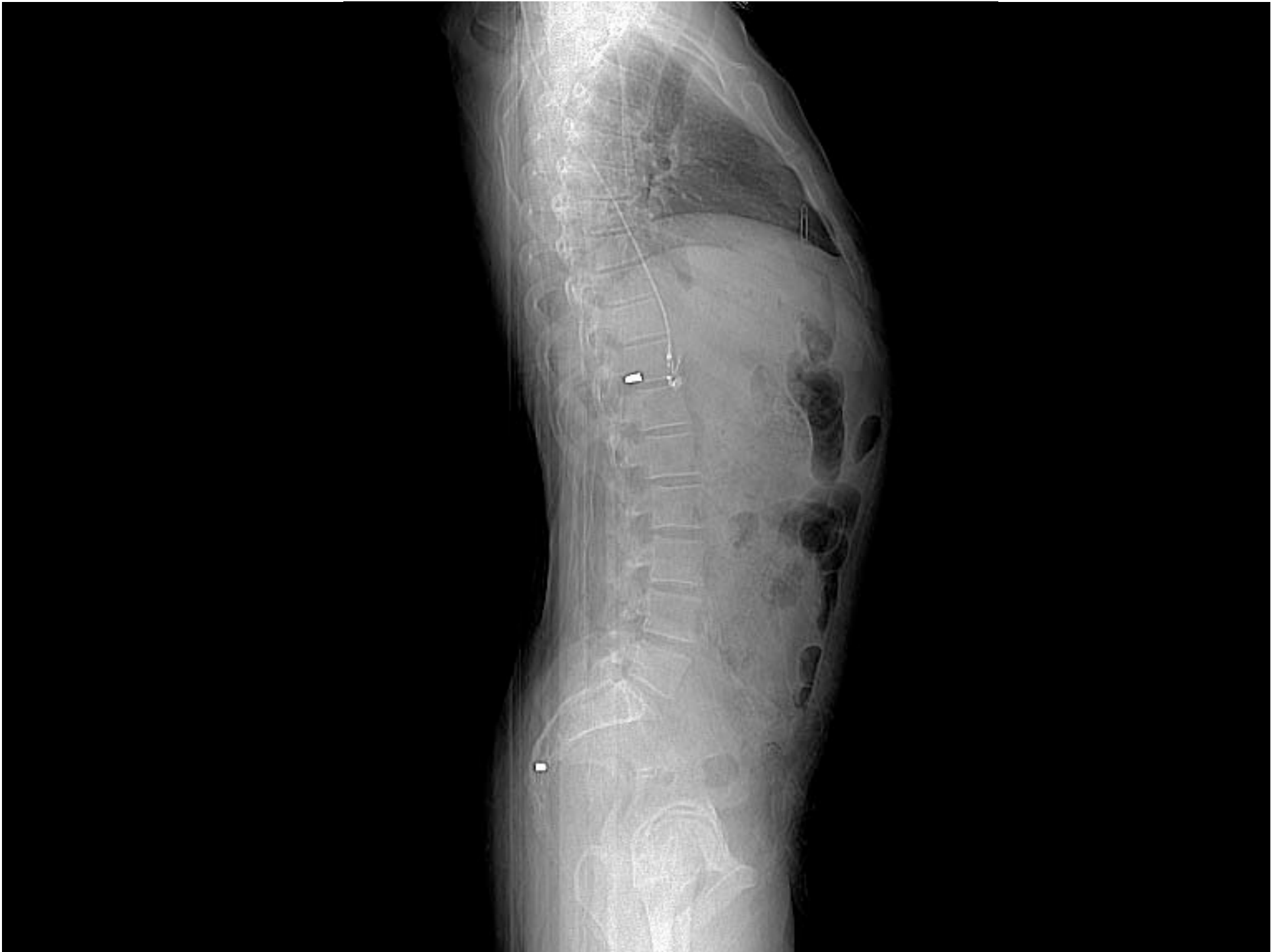---

- Xray
    - Chest
    - Abdomen
    - Pelvis
  
  - FAST
    - ?
  
  - ABG
    - Hb 15, BE -6.4, pH 7.42
-



Where is the  
bullet marker ?





# CT or operation ? Chest tube ?

---

## CT

- Lung injury
- Free intraabdominal air
- Bullet at T 10

## Chest tube

## Laparotomy

- No blood
- Ruptured diaphragm
- Stomach front and back
- Serosal tear transverse colon

## Closure

---

